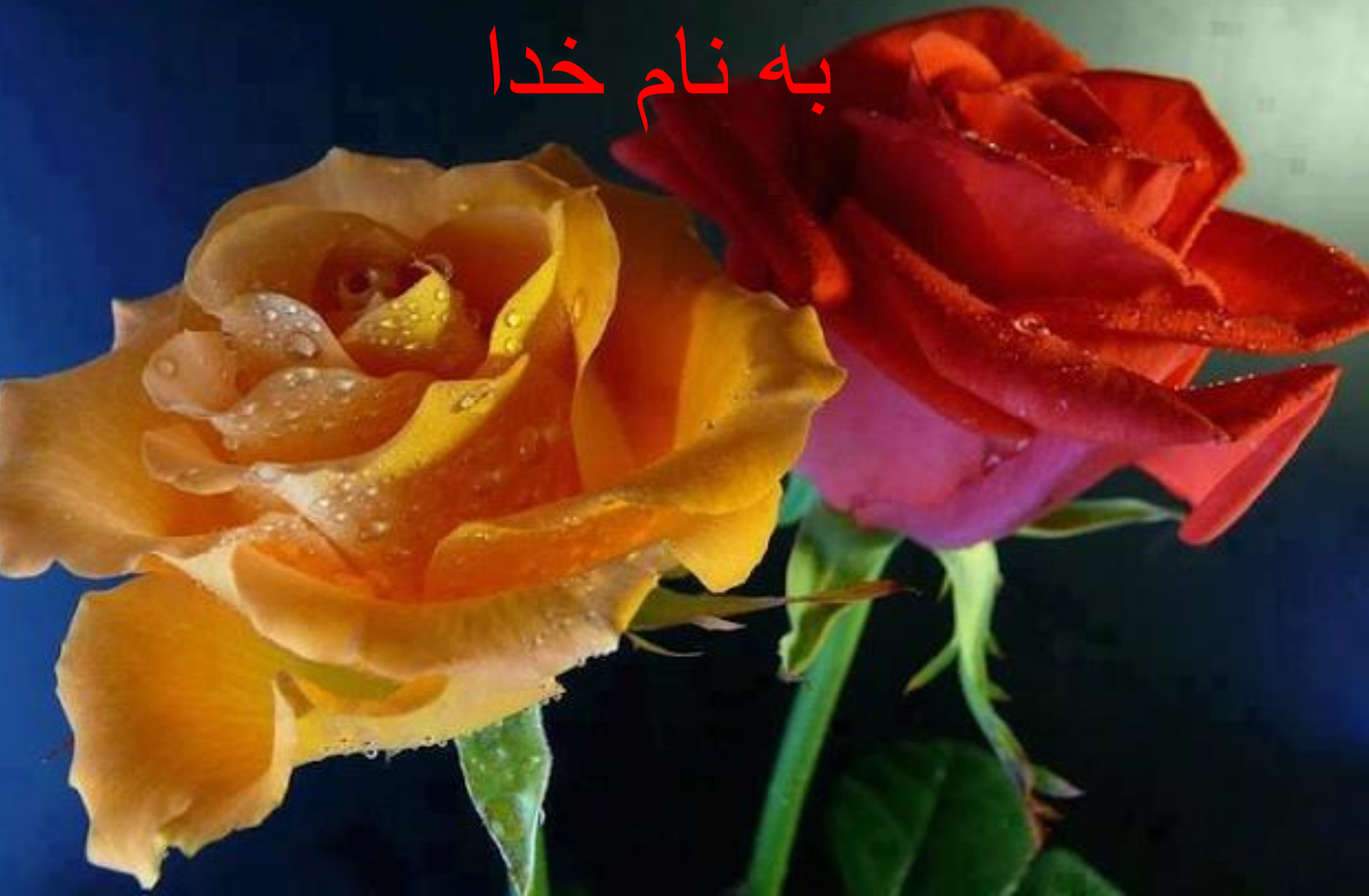

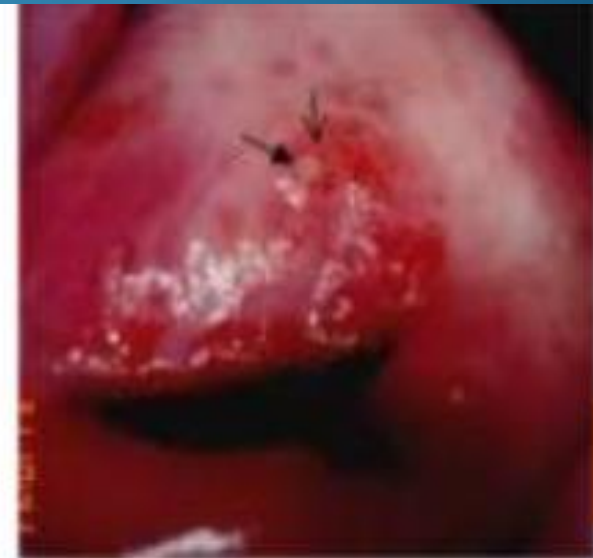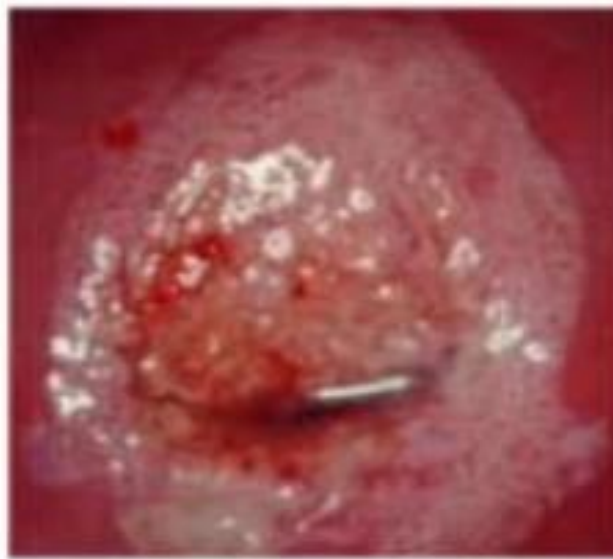
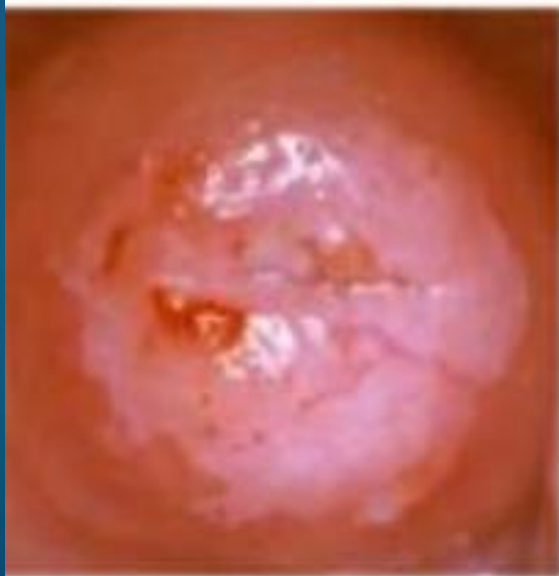به نام خدا



# Colposcopy

*P.M.Gharabaghi-MD*

1400



# WHAT IS COLPOSCOPY?

- *Colposcopy is a **gynecological procedure** that illuminates and magnifies the vulva, vaginal walls, and uterine cervix in order to detect and examine abnormalities of these structures*



# ***INTRODUCTION of COLPOSCOPY***

- *The primary goal of colposcopy is to identify **precancerous and cancerous lesions***
- *Malignant and premalignant epithelium have specific visual characteristics in terms of contour, color, and vascular pattern that are recognizable using colposcopy*

# ***INDICATIONS OF COLPOSCOPY***

***Follow-up test to evaluate abnormal  
cervical cancer screening tests  
(cytology and/or human  
papillomavirus testing***

***[www.asccp.org](http://www.asccp.org)***



# ***INDICATIONS OF COLPOSCOPY***

- ***Cytology negative, but HPV positive woman > age 30***
- ***Persistent ASC-US or LSIL between ages 21-24 years***
- ***ASC-US with positive high risk HPV***
- ***ASC-H regardless HPV status***
- ***LSIL***
- ***HSIL***
- ***AGC***

# **INDICATIONS OF COLPOSCOPY**

- *Persistent postcoital bleeding*
- *Persistent vaginal discharge*
- *In uterus exposure to DES*
- *Evaluation of a palpably or visually abnormal cervix, vagina, or vulva*
- *Evaluation of a positive screening test for cervical neoplasia such as :visual inspection with acetic acid or Lugol iodine, cervicography, or speculoscopy*



# ***INDICATIONS OF COLPOSCOPY***

***In conjunction with treatment of cervical neoplasia with laser or other treatment modalities:***

- ***To ensure that known lesions are completely removed or treated***
- ***To detect any other lesions in surrounding areas***
- ***For posttreatment surveillance***

***It is not an effective screening tool for cervical cancer when used alone***

- ***Wart??????***



# ***genital warts***

- *Women with genital warts should undergo speculum examination to evaluate for vaginal or cervical involvement*
- *Cervical cancer screening should be performed according to standard guidelines*

# CONTRAINDICATIONS OF COLPOSCOPY

- *No absolute contraindications*
- *Cervicitis :treat active cervicitis*
- *Treat (Trichomonas vaginalis), before the examination because inflammation and infection impede accurate assessment of epithelial abnormalities*
- *Other vaginal infections do not affect visualization with colposcopy*
- *Treatment of vaginitis before colposcopy may allow the patient to be more comfortable during the examination*

# CONTRAINDICATIONS OF COLPOSCOPY

- *Anticoagulation or bleeding diatheses are not contraindications to colposcopy*
- *Bleeding is usually minimal, even in women with these issues*
- ***Immunosuppression***
- *Patients who are severely immunosuppressed (absolute neutrophil count <500 cells/microL) are at risk for bacterial translocation and potential bacteremia from a speculum examination*
- *Colposcopy should be avoided in these patients in most circumstances*

# CONTRAINDICATIONS

- ***Pregnancy***
- *The physiologic changes to the cervix during pregnancy (eg, hyperemia) make colposcopy and identifying cancerous lesions more difficult*
- *Morbidity associated with cervical conization or biopsy during pregnancy is substantial*
- *Biopsy is only performed if invasive disease is suspected*

# ***INSTRUMENTATION AND EQUIPMENT***

- *The colposcope is a lighted binocular microscope that magnifies the tissue of interest*
- *Helping to identify features suggestive of abnormal tissue*

# ***INSTRUMENTATION AND EQUIPMENT***

- ***Colposcopes magnification can range from 3.5x to 30x***
- ***Medium power 15x for the cervix and vagina***
- ***Low power 3.5 to 7.5x for vulva***
- ***High power for close inspection of vascular patterns***
- ***The examination should begin with white light at a low-power setting for a global view of the cervix***
- ***Green filter light may help identify vascular changes***

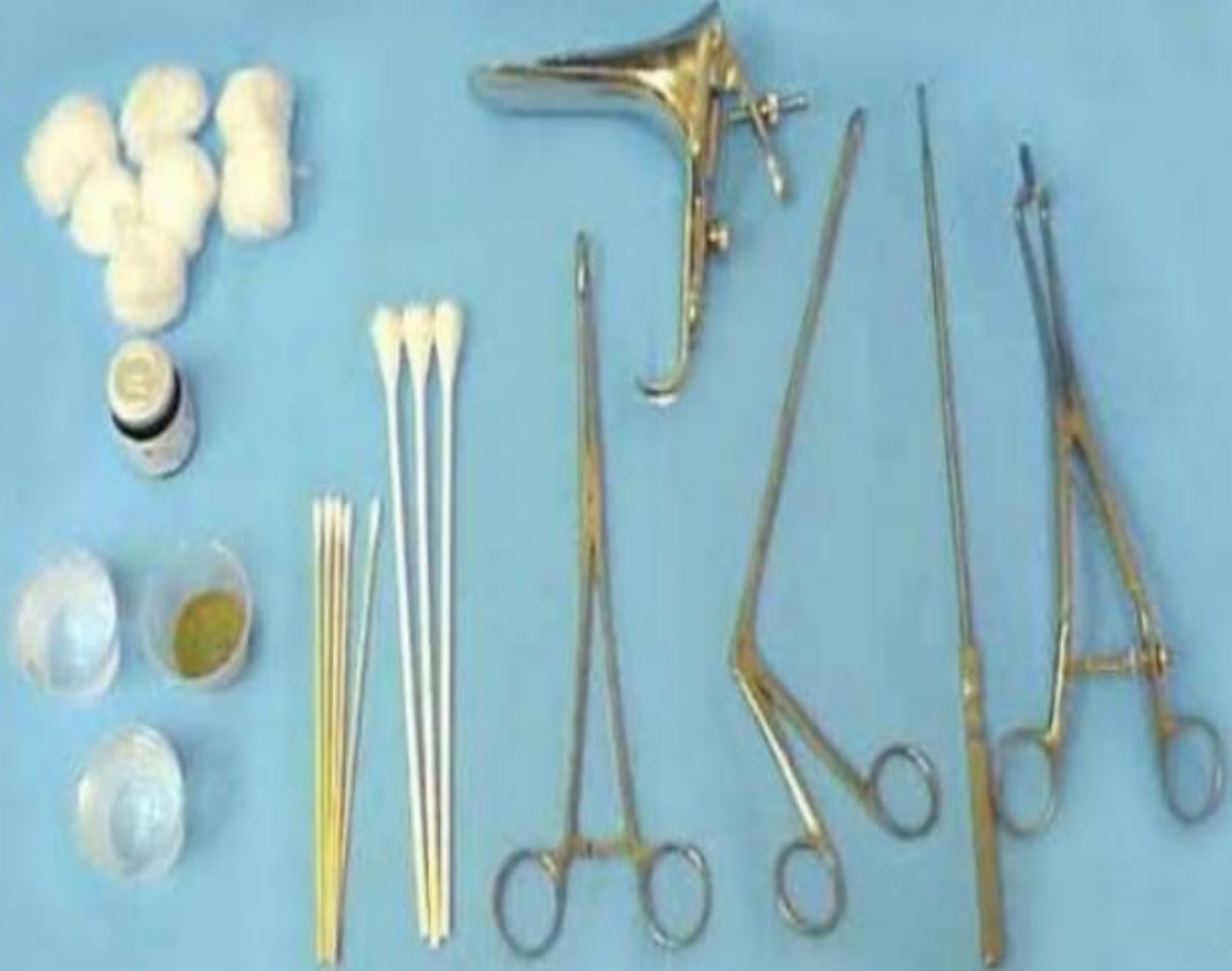

# ***Specifications and set-up of the colposcope include***

- ***Adjust the intraocular distance between the two eyepieces on the colposcope to ensure binocular vision***
- ***The colposcope should be placed approximately 30 cm from the tissue that is being visualized***

# ***Other supplies and instruments***

- ***Biopsy instruments***
- ***Solutions needed for the examination  
(eg,  
acetic acid)***
- ***Solutions needed for control bleeding  
(eg, Monsel solution)***





- ***PREPROCEDURE  
PREPARATION***

## ***The lower genital tract history and review of records should include:***

- ***Prior cervical cytology (Pap test) and human papillomavirus tests, normal and abnormal***
- ***Prior cervical, vulvar, and vaginal biopsy results***
- ***History of lower genital tract cancers or precancers***
- ***History of condyloma (genital warts)***
- ***Treatments to the cervix, vagina, and vulva***

# ***Review of history and records***

***we request the slides and have them reviewed by our pathology laboratory if:***

- 1- The patient is seeing us for a second opinion***
- 2- There is a discrepancy between the cytology and biopsy result (especially when the cytology results is a HSIL or adenocarcinoma in situ and we are unable to find a lesion on colposcopic examination that explains this abnormality***



# *medical history*

- *Obstetric and gynecologic history*
  - *Last menstrual period*
  - *History of sexually transmitted infections*
  - *Birth control method*
  - *History of cervical or pelvic surgery*
- *Immunosuppression*
- *Smoking history*
- *● Factors that impact the safety of the procedure*
  - *Anticoagulation*
  - *Bleeding disorders*
  - *Allergy to iodine*

# ***Informed consent and counseling***

- *Explain the procedure*
- *Questions should be answered*
- *The discussion is documented and signed*
- *Anxiety, pain, and compliance with follow-up after colposcopy improved by :*
- *showing an informational video before colposcopy*
- *playing music during colposcopy,*
- *viewing video colposcopy during the procedure*
- *providing a visual distraction such as a picture on the ceiling*

# ***cervical colposcopy procedure***

- *Abnormal colposcopic findings are used to choose the sites to biopsy*
- *colposcopic findings themselves are not diagnostic of cervical neoplasia*
- *This can only be established definitively by pathologic examination of the biopsied tissue*

# *The procedure*

- *The patient is placed in the dorsal lithotomy position*
- *The vulva is examined under gross visualization for any suspicious lesions or findings that require biopsy or colposcopic examination*
- *A speculum is placed in the vagina; it is best to use the largest speculum that the patient can easily tolerate so that the entire cervix and vaginal fornices may be visualized*
- *Colposcopy is typically well-tolerated, and anesthesia or analgesia are not usually required*

# *procedure*

- *Repeat cytology and HPV testing (6 weeks)*
- *Abnormal cervical cytology findings (LSIL, HSIL) may resolve or progress over time*
- *A current cytologic result enables the colposcopist to make the most accurate correlation of cytologic, colposcopic, and histologic findings*
- *Traditionally, it was advised that the interval between cervical cytology tests be at least six weeks, but it appears that shorter intervals do not compromise the adequacy of the specimen*

# ***Gross visualization***

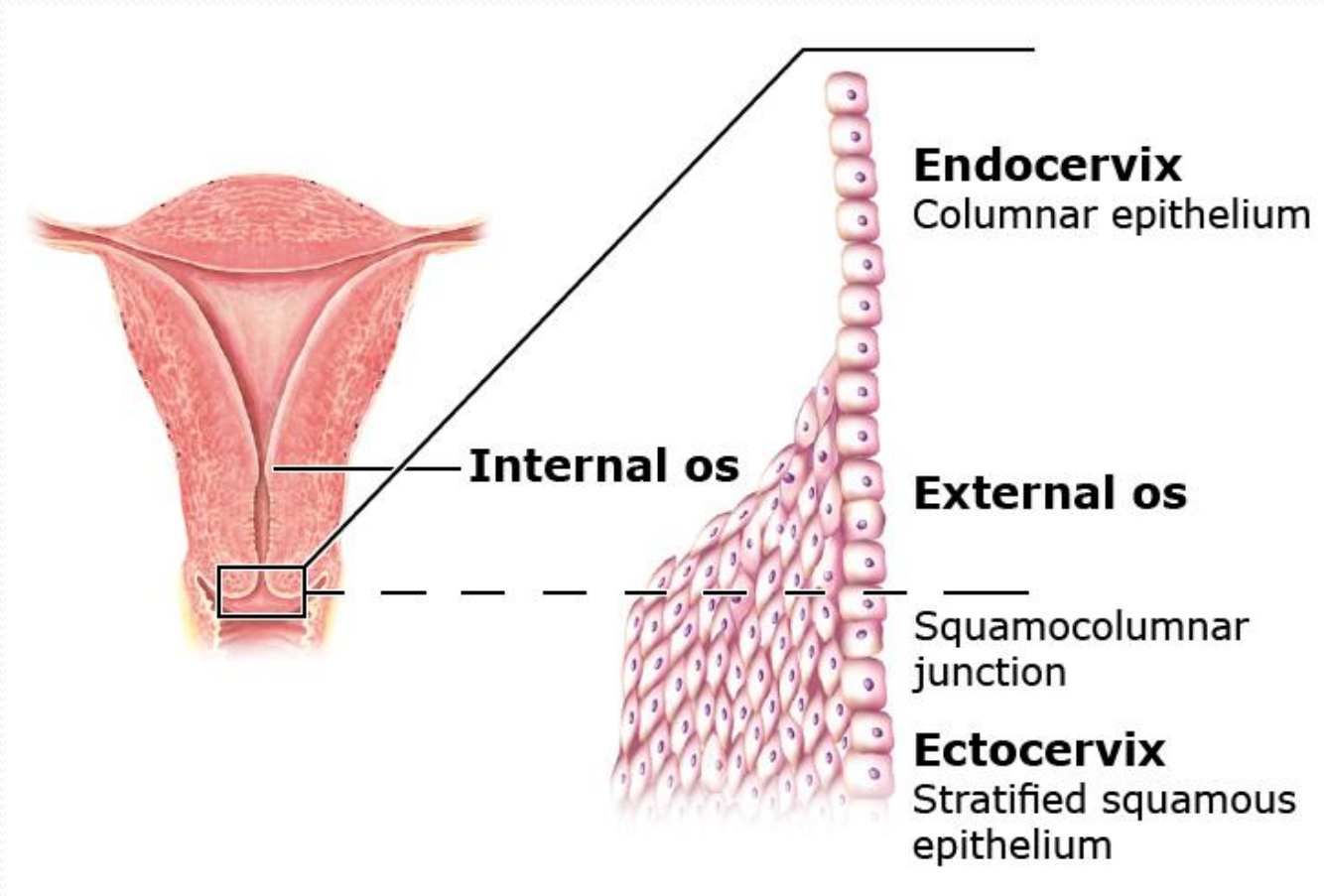
- *The cervix and vagina are first examined under gross visualization with a bright light, without application of solutions to identify abnormalities*
- *If the view of the cervix is occluded (mucus, blood, discharge, or debris), cotton soaked in saline may be used to cleanse it*
- *The clinician should look for and define :*
  - *Erosion*
  - *Ulceration*
  - *Irregular surface of ectocervix*
  - *Leukoplakia*
  - *Pigmented lesions*
  - *Exophytic growth*



# ***Colposcopic examination***

- *The colposcope is used to examine the entire surface for the cervix, but the most emphasis is put on examining the SCJ and transformation zone*
- *The SCJ (junction of squamous and glandular cells, generally at the external cervical os)*
- *The transformation zone (transformation zone is the area between the original SCJ and the current one) are the areas at greatest risk for neoplasia*

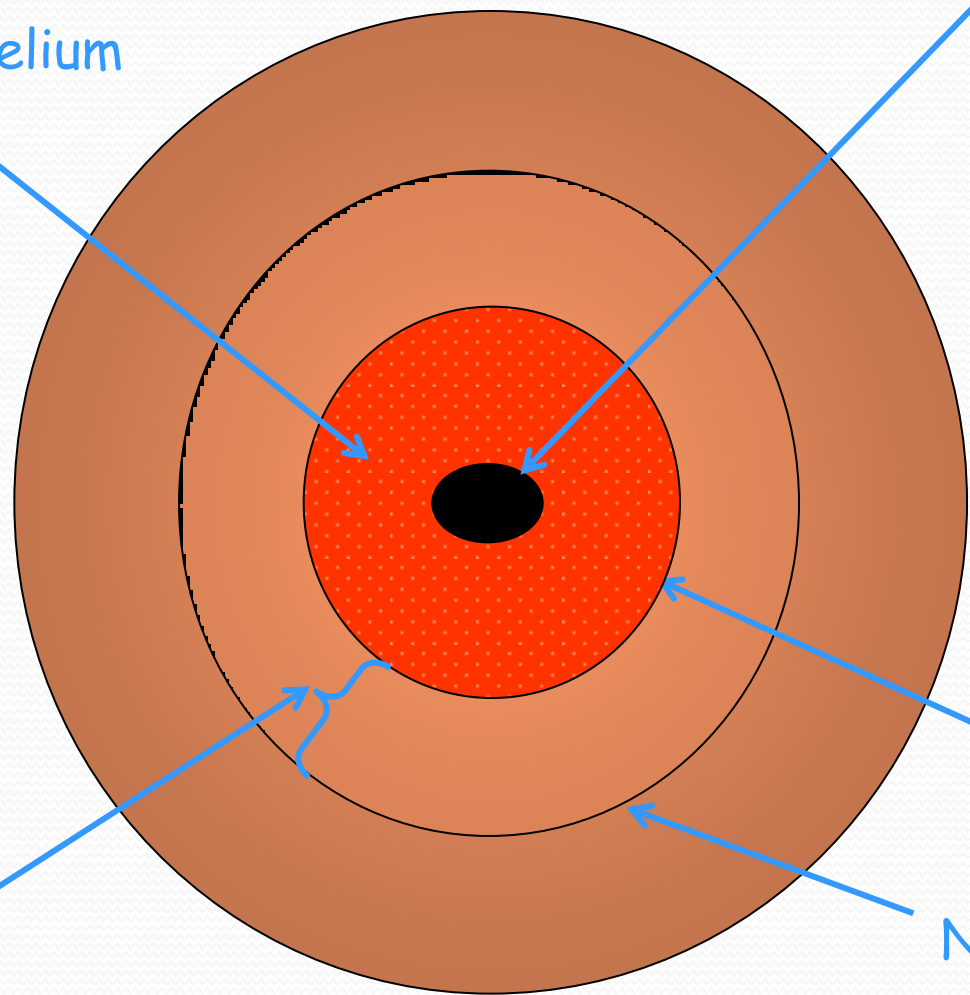
# Uterine cervix anatomy and histology



Cell types comprising the transformation zone. The endocervix is lined by columnar epithelium. The ectocervix is lined with stratified squamous epithelium. The squamocolumnar junction marks the merging point of these two epithelial cell types.

Glandular epithelium  
(Ectropion)

External os

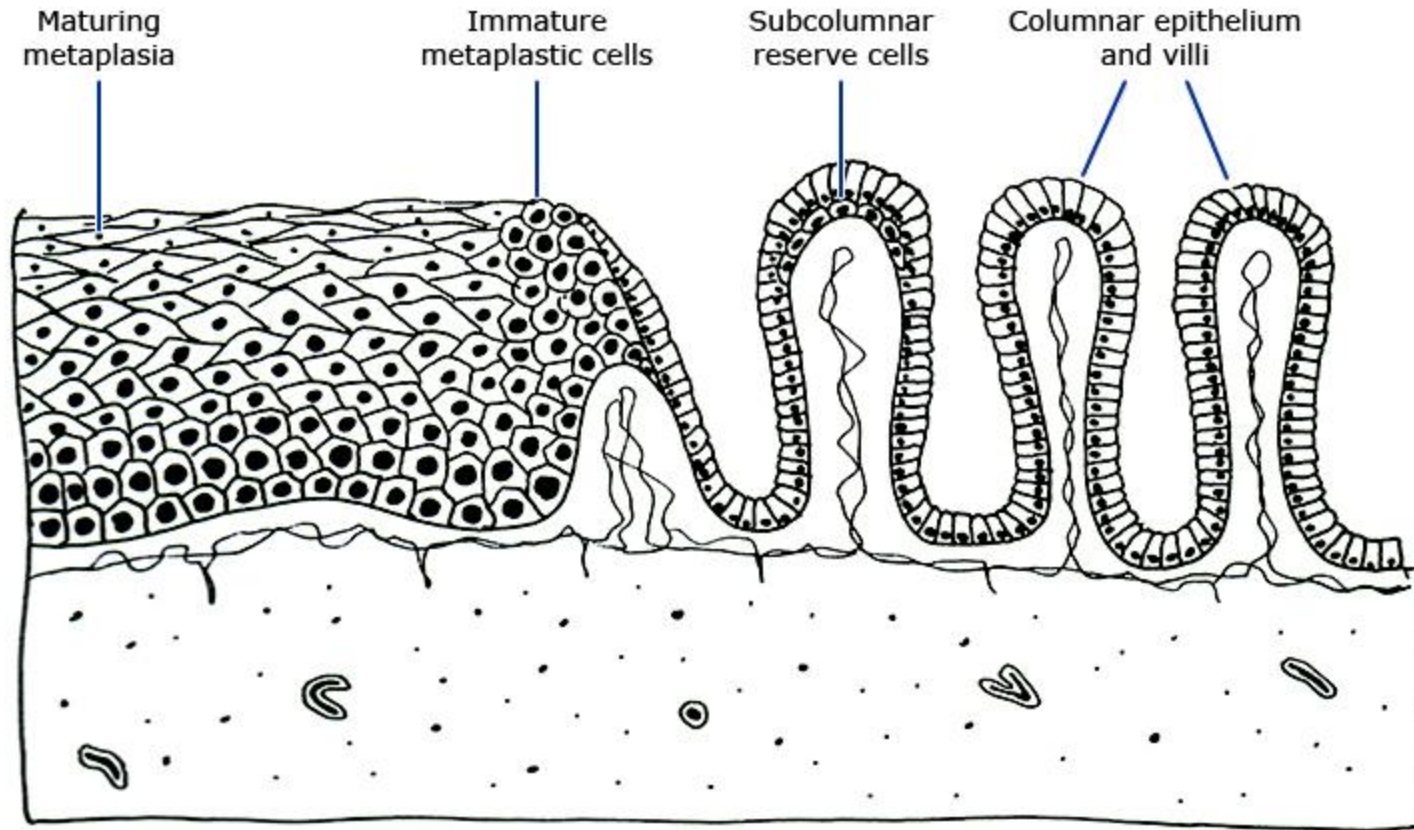


Transformation zone  
Area of metaplasia

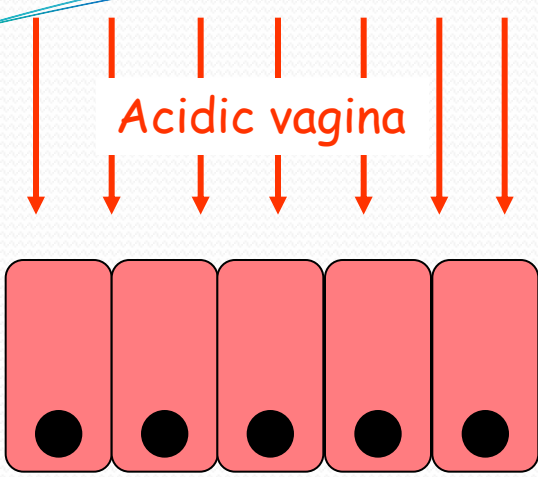
New Sq Col Jun

Native Sq Col Jun

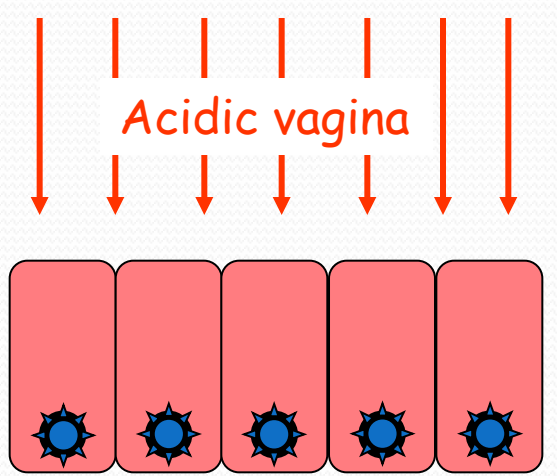
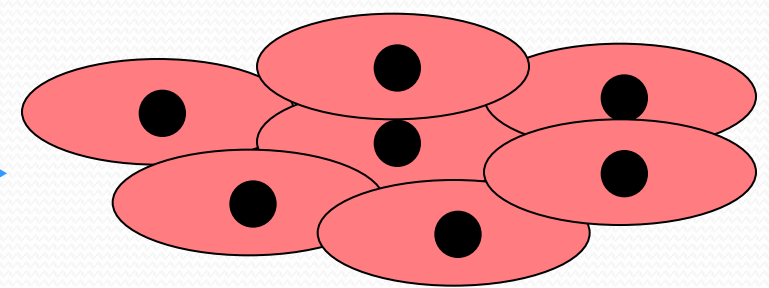
## Cervical transformation zone histology



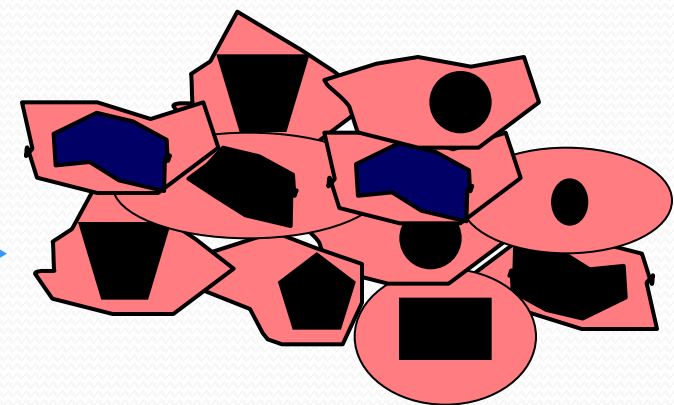
The active T-zone has immature metaplasia at the squamocolumnar junction as the squamous cells migrate over the villi. When they form glycogen, they become mature and are resistant to human papillomavirus infection.



Metaplasia



Dysplasia



# *Application of acetic acid*

- *The cervix is examined first without, and then with a solution of 3 to 5 percent acetic acid*
- *After **30 to 60** seconds, the acidic solution dehydrates cells so that squamous cells with relatively large or dense nuclei (eg, metaplastic cells, dysplastic cells, cells infected with HPV) reflect light and thus appear white **acetowhite***
- *Blood vessels and columnar cells are not affected but become easier to visualize against the white background*
- *Fading of acetowhite changes occurs after **three minutes***
- *The acetic acid should be reapplied, as needed, after this time*
- *Excessive acetic acid pools in the vagina, should be removed with dry swabs, as it can cause irritation*



# **Schiller Test**

- *If no lesions are seen after acetic acid is applied, a dilute Lugol or Schiller solution may be applied to the cervix and vagina to aid in detection*
- *Uniform uptake of stain would confirm the colposcopist's impression that no lesion is present*
- *Glycogen-containing cells will take up iodine and become dark brown*
- *Nonglycogenated cells, such as normal columnar or glandular cells, high-grade lesions, and many low-grade lesions, will not take up iodine and remain light yellow*

## ***Differential light absorption by squamous versus glandular cells***

- *The squamous cells of the ectocervix have a smooth grey-pink appearance*
- *The glandular cells of the endocervix have a pink-red cobblestone appearance*

### ***Use of the green or blue filter on the colposcope***

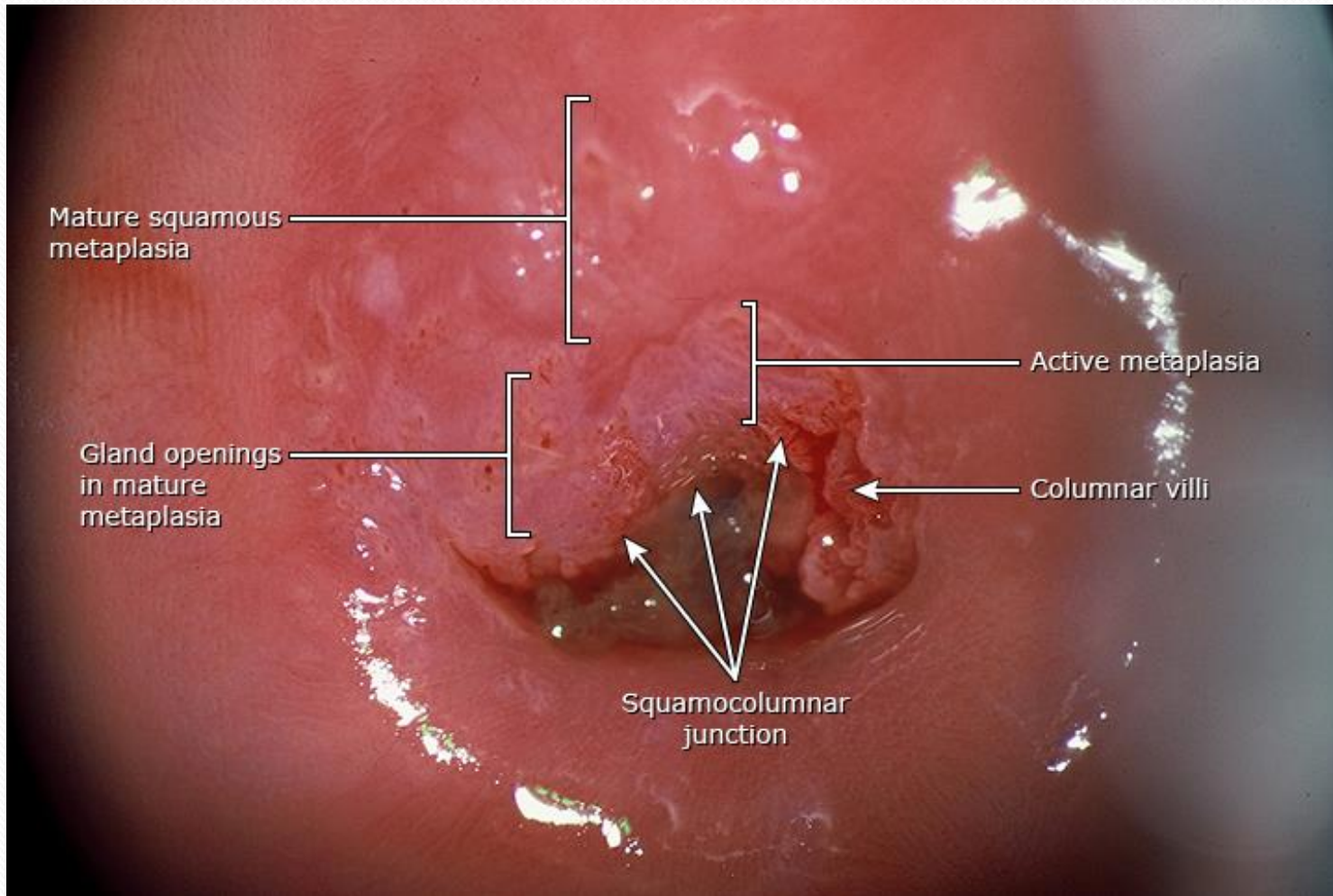
- *Accentuate abnormal vasculature*
- *Blood vessels appear darker and this sharpens the contrast between vessels and the surrounding epithelium*



# ***Colposcopic examination***

- *After the cervix is examined, the upper one-third of the vagina, in particular the lateral fornices, is also examined*
- *The transformation zone and SCJ may extend into the upper vagina, particularly in younger patients*

## *Cervical transformation zone at colposcopy*



A cervical transformation zone with mature metaplasia and active immature metaplasia.

# ***Approach to a difficult colposcopy***

- *The SCJ is always a circumferential region around the external cervical os*
- *The distance between the os and the edges of the junction varies*
- *In some women, the distance between the os and the edges of the junction is narrow or the SCJ is not visible because it recedes within the endocervical canal*

# ***The location and size of the junction is altered by several factors:***

***Hormonal factors –high serum estrogen levels (eg, pregnancy, oral contraceptives) cause the SCJ to be more everted***

- ***If a great degree of eversion is present, the columnar epithelium is exposed to the vaginal milieu; this is referred to as ectropion***
- ***Ectropion is common during pregnancy or in adolescents***
- ***Menopause may cause the squamocolumnar to recede into the cervical canal***

## ***Prior cervical treatments***

- Cervical conization with removal of transformation zone may make it difficult to visualize the current SCJ or the upper margin of a lesion*
- An endocervical speculum or a wet cotton swab (less traumatic) can be placed on the ectocervix to pull the tissue aside and open the os*

# ***Findings***

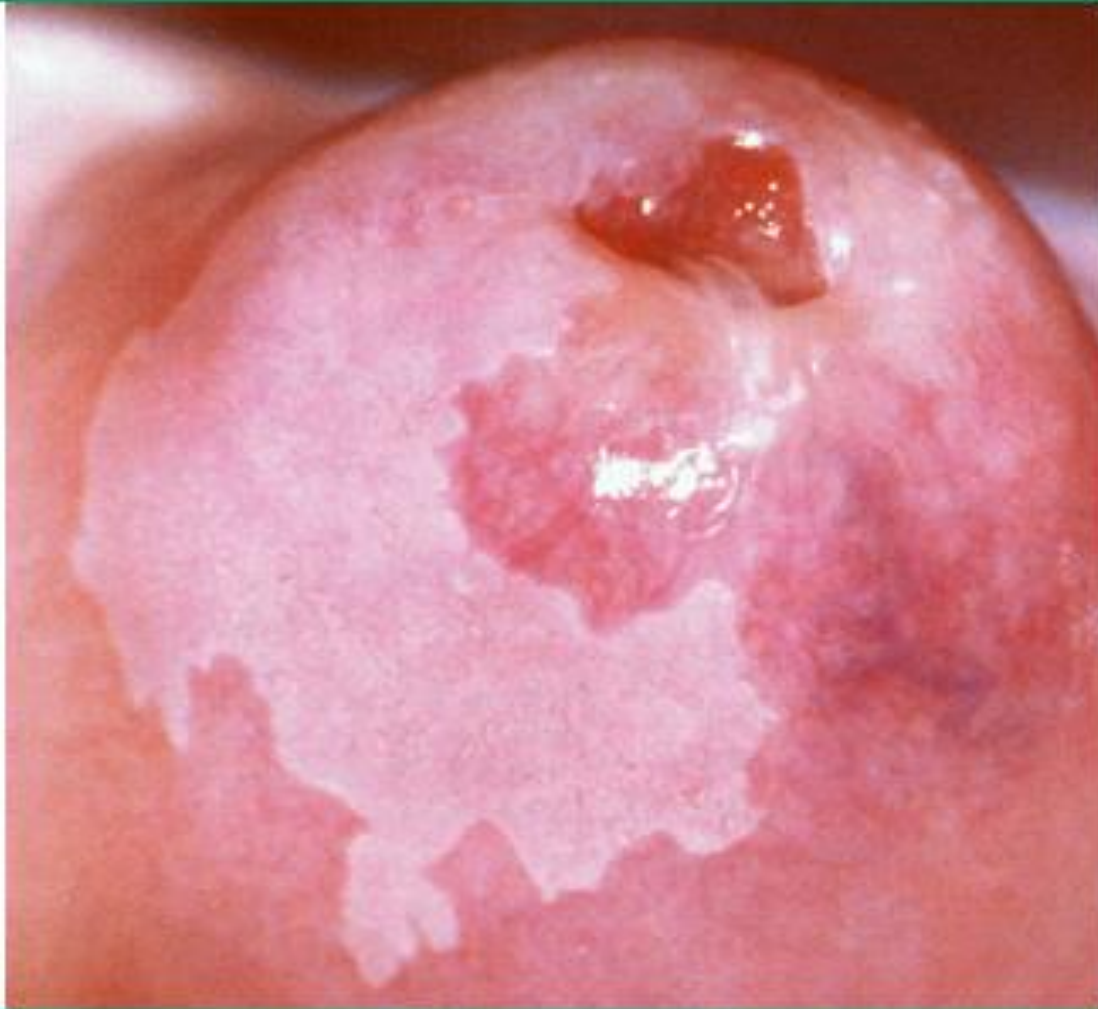- *The locations of abnormalities are noted as on the face of the clock (eg, at 2:00 or 10:00)*
- *The type and characteristics of an abnormality may correspond with the grade of the abnormality*
- *However, a colposcopic impression is not diagnostic, and biopsies must be performed to obtain histologic results*
- *No colposcopic findings are pathognomonic for cervical cancer*

# *Abnormalities during cervical colposcopy*

- *Acetowhite epithelium*
- *with sharp borders are more likely to be **high-grade lesions***
- *With diffuse borders suggest **lowgrade disease***



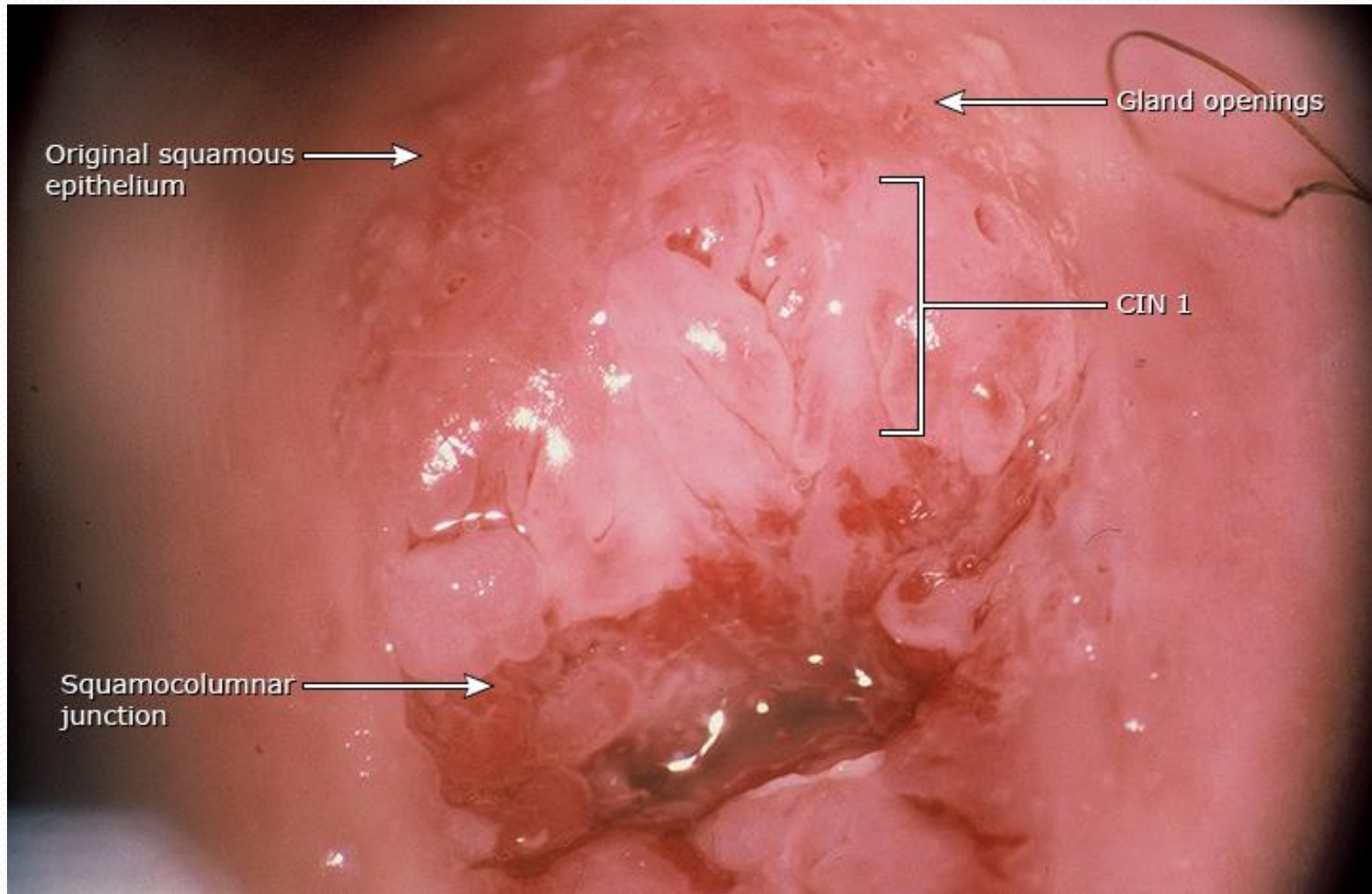
## Low grade cervical intraepithelial lesion



This lesion represents a geographic map-like, low-grade dysplasia. The lesion itself is irregular, and it extends to the posterior cervical portio.

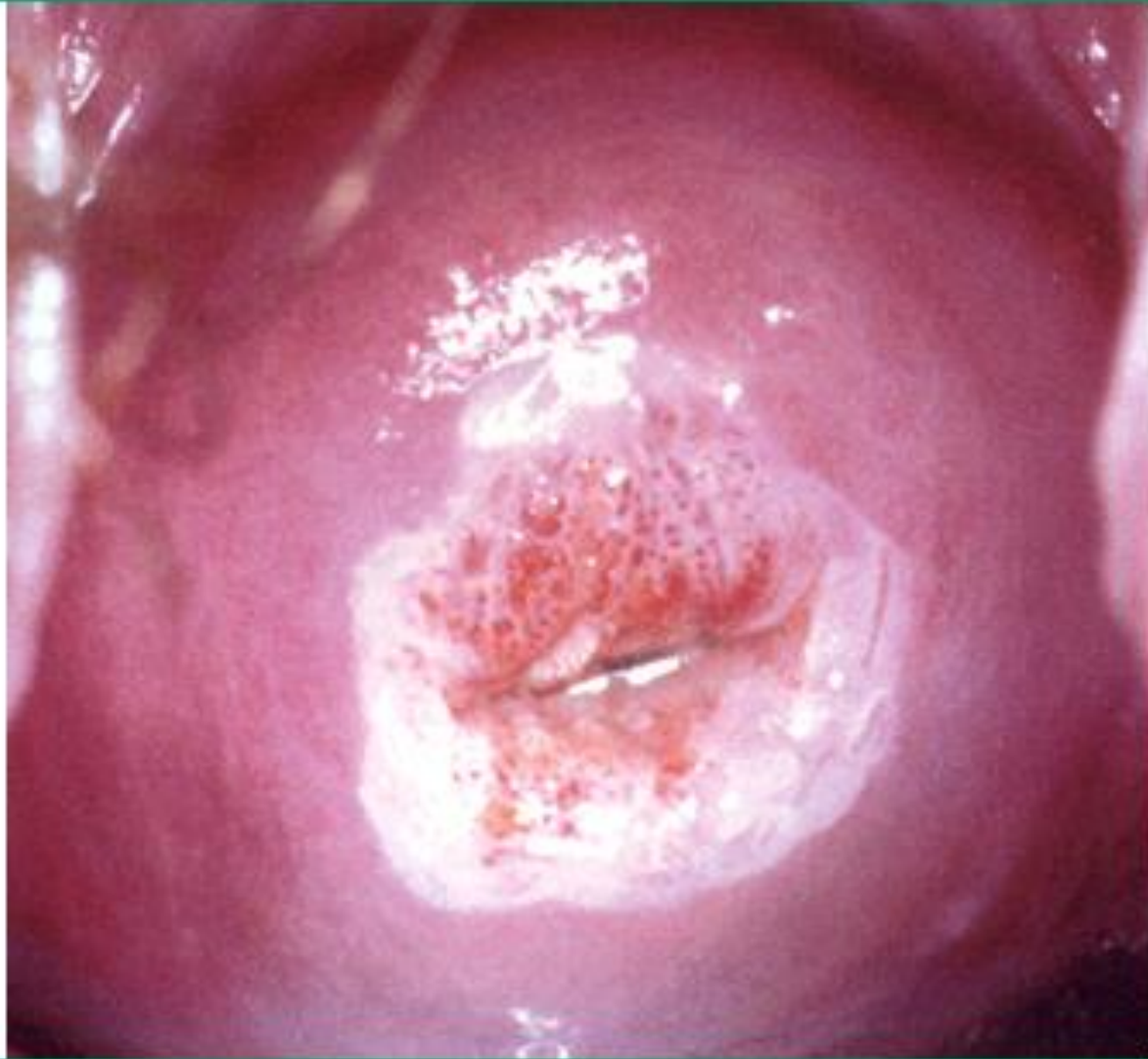

## Colposcopy of the cervix: Cervical intraepithelial neoplasia, low-grade



CIN 1 transformation zone completely seen.  
CIN: cervical intraepithelial neoplasia.

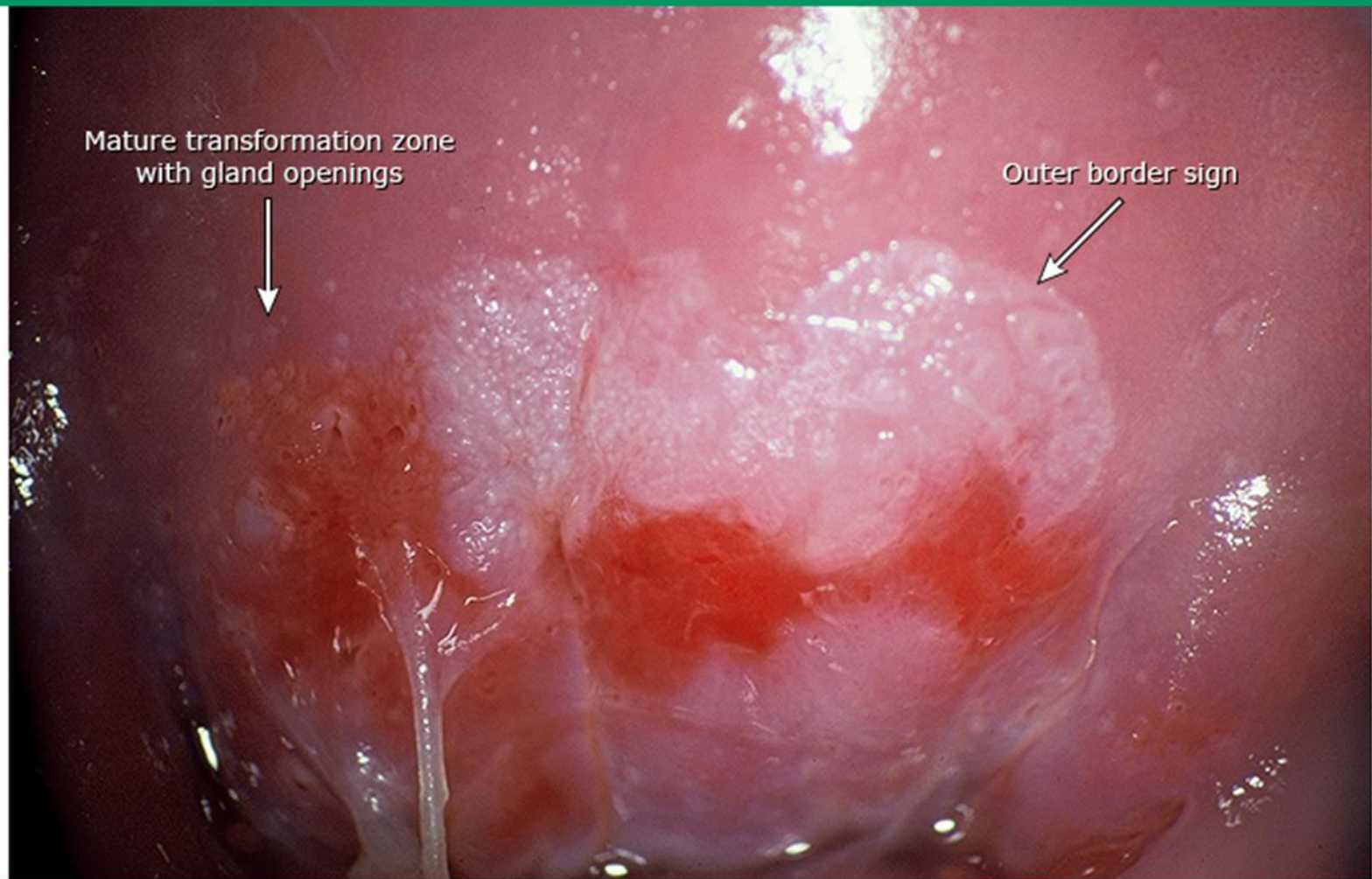
## High grade cervical intraepithelial lesion



Coarse punctation is seen on the anterior lip of the cervix.



## Colposcopy of the cervix: Cervical intraepithelial lesion, high-grade



CIN 2. The outer border is smooth and distinct.

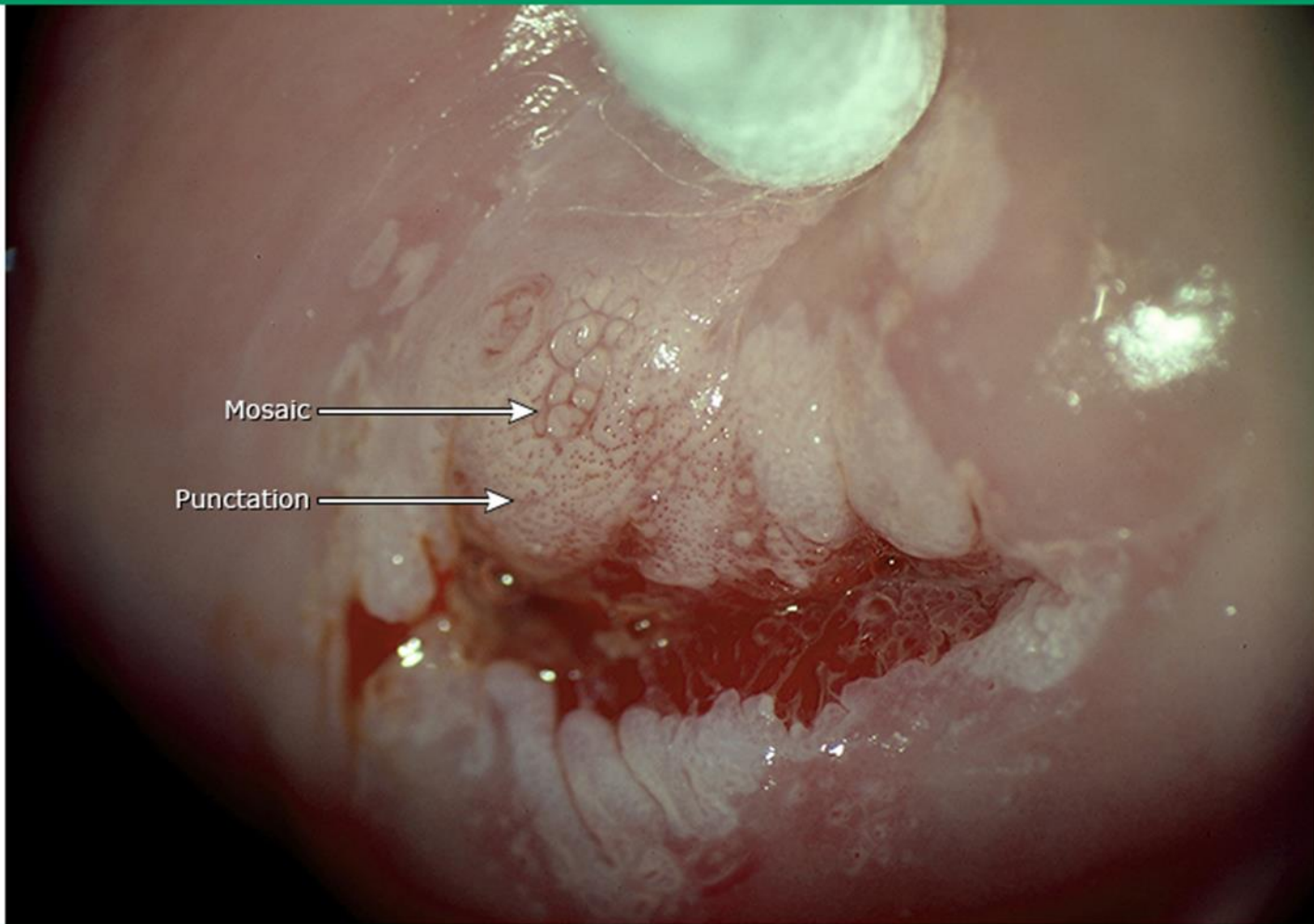
CIN: cervical intraepithelial neoplasia.

*Reproduced with permission from Kenneth Hatch, MD, University of Arizona, Department of Obstetrics and Gynecology.  
Copyright © 2016.*

# ***Abnormal vascular patterns***

- ***Mosaicism*** – *Punctate and mosaic vessels in a field of acetowhite epithelium in the transformation zone are suggestive of CIN, low-grade or high-grade*
- ***Punctation*** – *should be differentiated with a stippled appearance beyond the transformation zone that may be found in patients with vaginitis*
- ***Atypical vessels*** – *Atypical vessels that have increased caliber (coarseness); display irregular and abrupt changes in direction; are widely spaced; suddenly terminate; or have corkscrew, comma, or hairpin patterns are suggestive of microinvasive or invasive disease*

## Colposcopy of the cervix: Punctation and mosaicism with swab technique to evert transformation zone

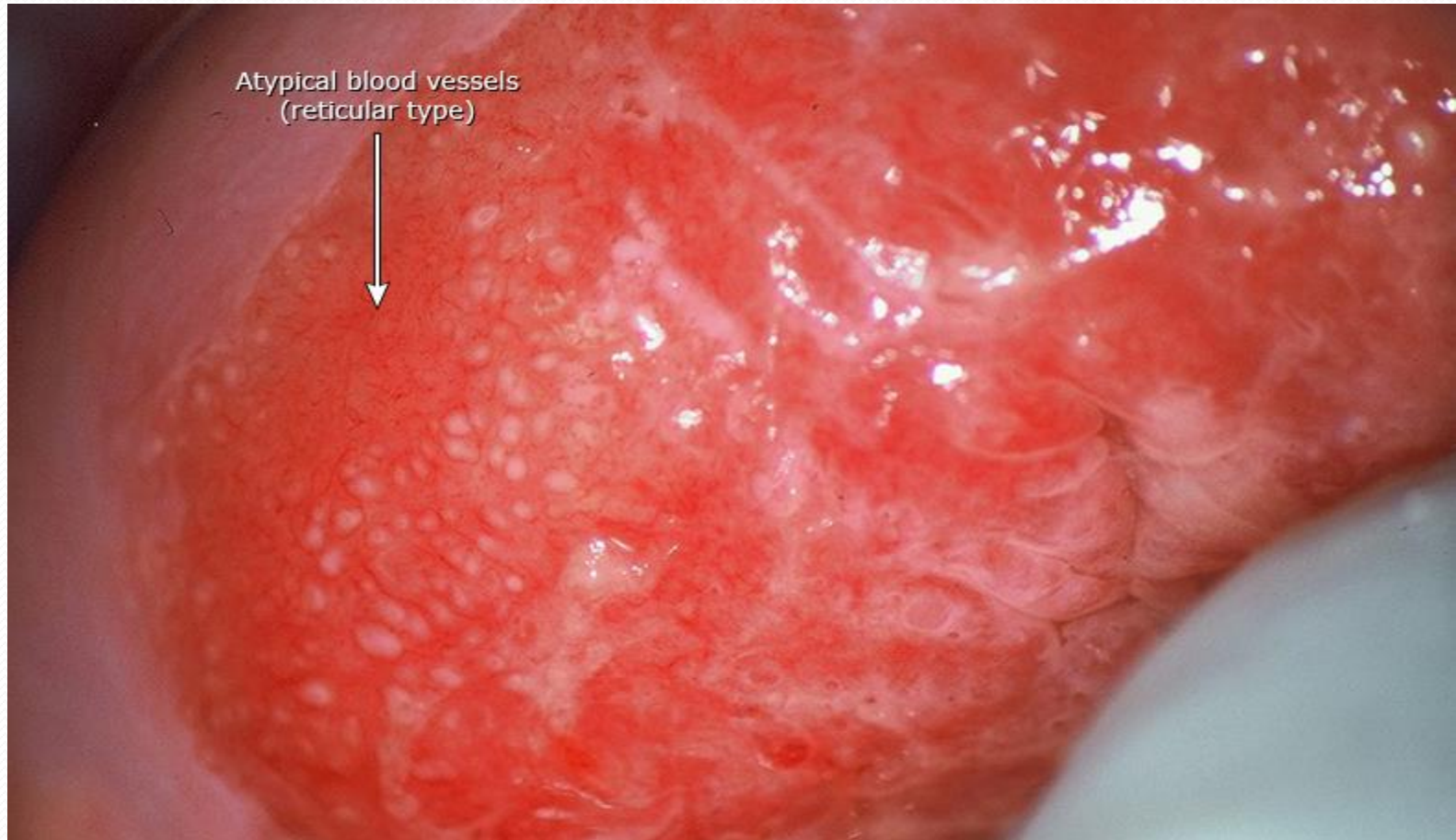

Cotton swab is used to evert the anterior lip of the cervix to see the entire lesion. With complete visualization of the transformation zone, examination is adequate.

*Reproduced with permission from Kenneth Hatch, MD, University of Arizona, Department of Obstetrics and Gynecology.  
Copyright © 2016.*

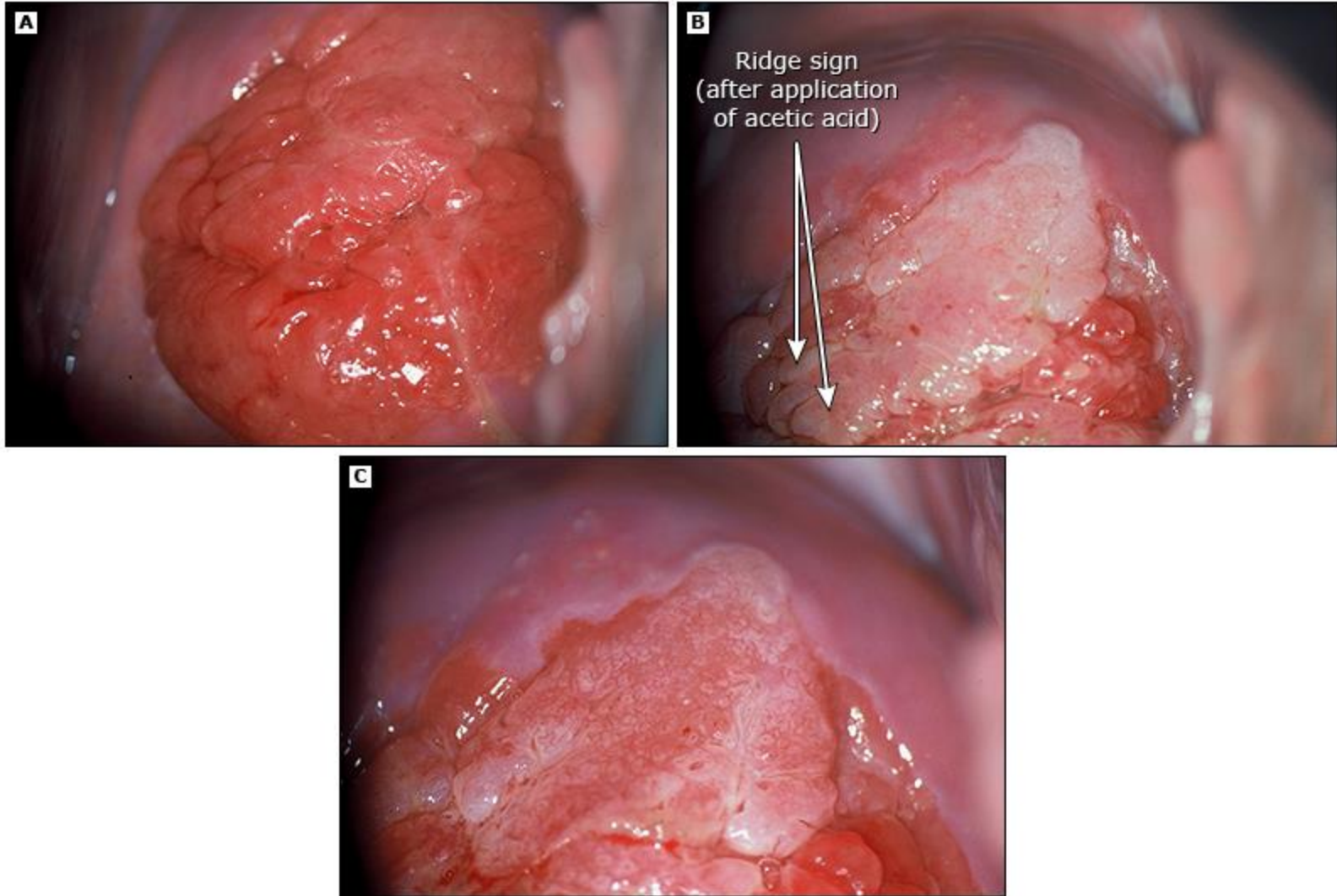


## Colposcopy of the cervix: Cervical intraepithelial neoplasia, high-grade with abnormal vessels




Cervical intraepithelial neoplasia, grade 3.

## Colposcopy of the cervix: Ridge sign and mosaicism



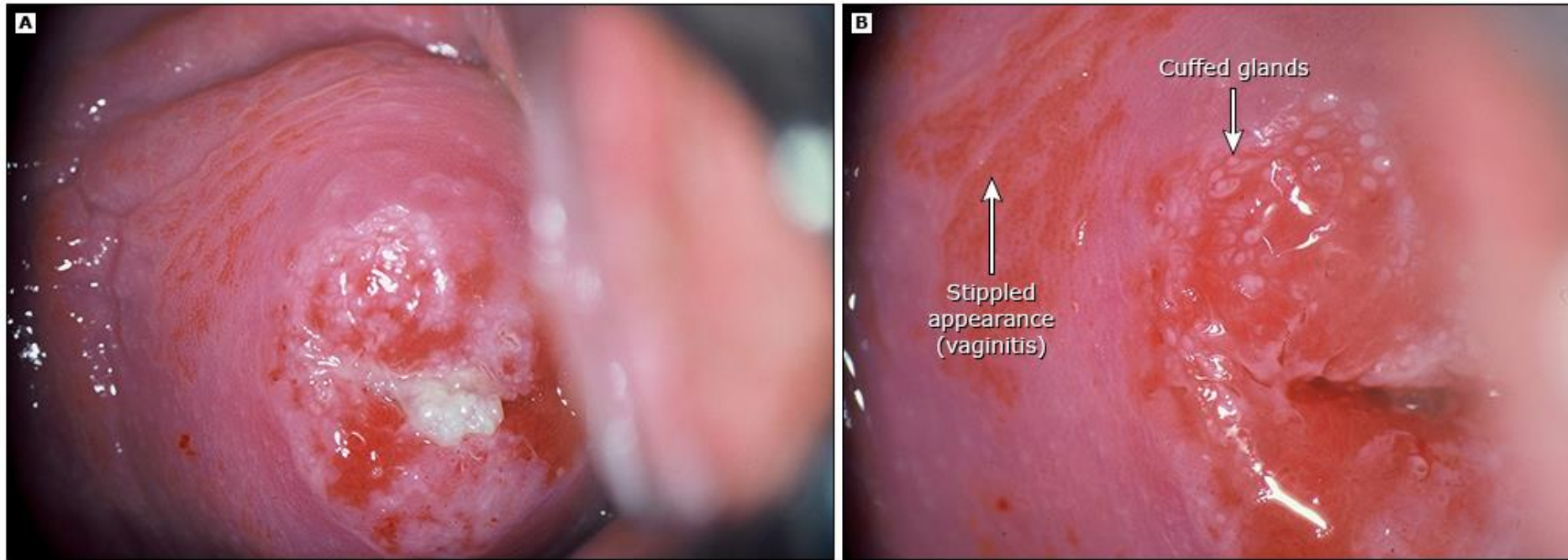
- (A) Large transformation zone before application of acetic acid.
- (B) After application of acetic acid, showing ridge sign.
- (C) After acetic acid has faded, showing mosaicism.



***Inflammatory changes on the cervix can appear similar to high-grade lesions, with diffuse mosaicism and cervical friability***



## Colposcopy of the cervix: Vaginitis



(A) Low-power view of cervix in a patient with high-grade cervical intraepithelial neoplasia (CIN<sub>3</sub>) and trichomonas vaginitis.

(B) Cervical intraepithelial lesion, grade 3. Cuffed gland sign, sometimes seen in high-grade cervical neoplasia. Stippled appearance consistent with trichomonas vaginitis and cervicitis.

## 2011 International Federation of Cervical Pathology and Colposcopy colposcopic terminology

Section	Pattern
General assessment	Adequate or inadequate for the reason (eg, cervix obscured by inflammation, bleeding, scar)
	Squamocolumnar junction visibility: completely visible, partially visible, not visible
	Transformation zone types 1, 2, 3
Normal colposcopic findings	Original squamous epithelium: mature, atrophic
	Columnar epithelium, ectopy/ectropion
	Metaplastic squamous epithelium, nabothian cysts, crypt (gland) openings
	Deciduous in pregnancy
Abnormal colposcopic findings	General principles
	Location of the lesion: inside or outside the transformation zone, location of the lesion by clock position
	Size of the lesion: number of cervical quadrants the lesion covers
	Size of the lesion as percentage of cervix
	Grade 1 (minor): fine mosaic; fine punctation; thin acetowhite epithelium; irregular, geographic border
	Grade 2 (major): sharp border, inner border sign, ridge sign, dense acetowhite epithelium, coarse mosaic, coarse punctation, rapid appearance of acetowhitening, cuffed crypt (gland) openings
	Nonspecific: leukoplakia (keratosis, hyperkeratosis), erosion
	Lugol's staining (Schiller's test): stained or nonstained
Suspicious for invasion	Atypical vessels
	Additional signs: fragile vessels, irregular surface, exophytic lesion, necrosis, ulceration (necrotic), tumor or gross neoplasm
Miscellaneous findings	Congenital transformation zone, condyloma, polyp (ectocervical or endocervical), inflammation, stenosis, congenital anomaly, posttreatment consequence, endometriosis

# ***Features suggestive of low-grade disease***

- ***Thin acetowhite epithelium***
- ***Irregular, geographic border***
- ***Fine mosaic***
- ***Fine punctation***

# ***Features suggestive of high-grade disease***

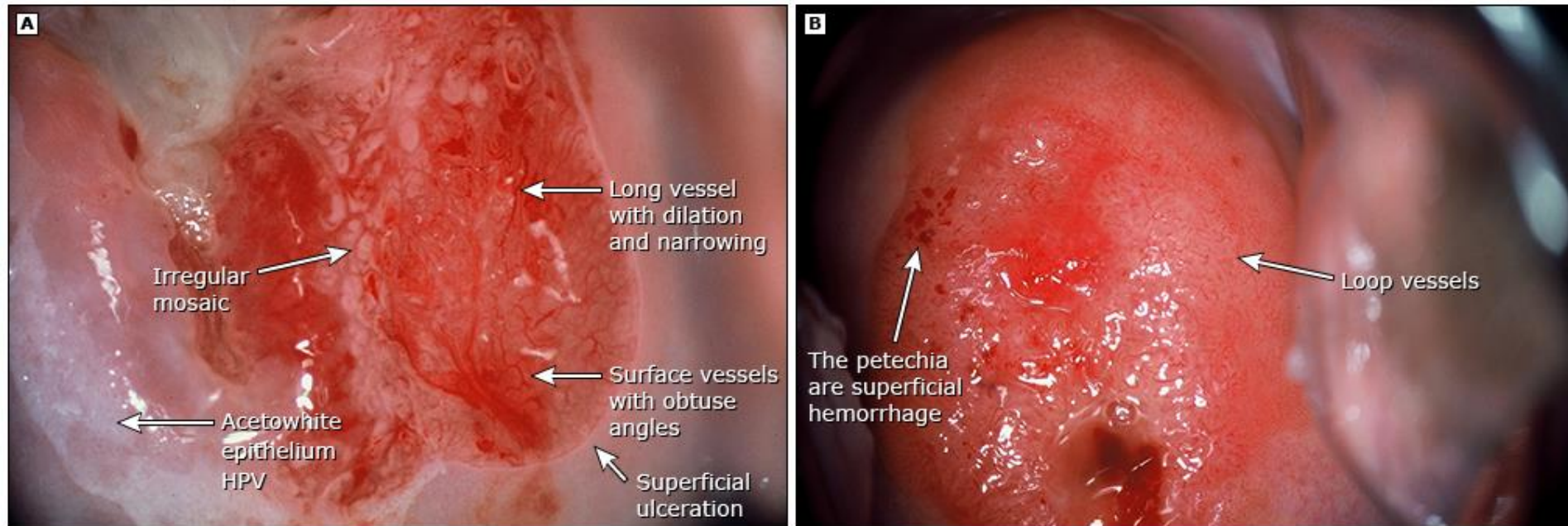
- ***Dense acetowhite epithelium***
- ***Rapid appearance of acetowhitening***
- ***Cuffed crypt (gland openings)***
- ***Coarse mosaic***
- ***Coarse punctation***
- ***Sharp border***
- ***Inner border sign***
- ***Ridge sign***

# ***Features suggestive of invasive cancer***

- *Atypical vessels*
- *Fragile vessels*
- *Irregular surface*
- *Exophytic lesion*
- *Necrosis*
- *Ulceration (necrotic)*
- *Tumor/gross neoplasm*



## Colposcopy of the cervix: Invasive cervical carcinoma

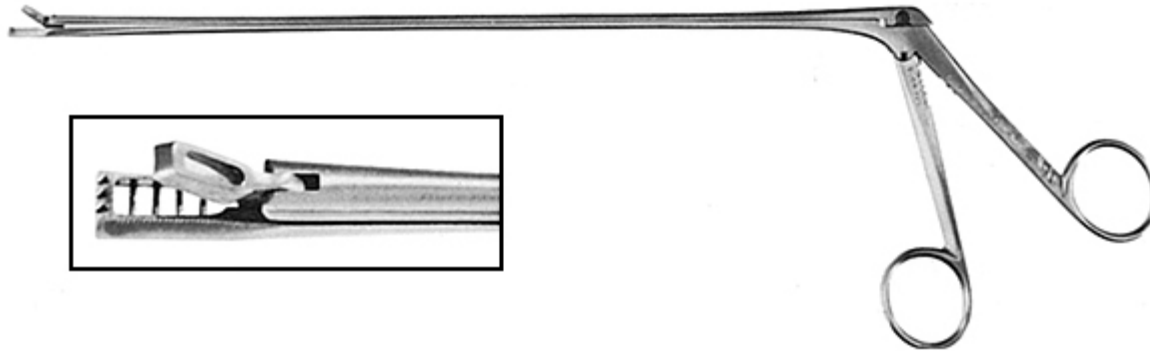


(A) Invasive cervical cancer, abnormal branching blood vessels.

(B) Invasive cervical cancer, abnormal loop blood vessels.

## Kevorkian cervical biopsy forceps

---



---

*Reproduced with permission from: Abu-Rustum NR, Ungar L, Alektiar K, Chi DS. Cancer of the cervix. In: TeLinde's Operative Gynecology, 11th ed, Jones HW, Rock JA (eds), Lippincott Williams & Wilkins, 2015. Copyright © 2015 Lippincott Williams & Wilkins ([www.lww.com](http://www.lww.com)). Unauthorized reproduction of this material is prohibited.*

Graphic 105214 Version 2.0

# ***Biopsies***

- *The amount of tissue removed is approximately 1 to 2 mm (**punch biopsies**)*
- *Local anesthesia is not used for biopsies of the cervix and upper vagina, since injection is as painful as the biopsy*
- *Injection of an anesthetic may also disrupt the epithelium, making visualization of the lesion more difficult*
- *Distraction techniques are as effective as local anesthetic injection( ask the patient to cough and perform the biopsy)*
- *Topical and oral analgesics are ineffective*



# ***Biopsies***

- *Each specimen is individually labeled according to its location on the cervix*
- *Each biopsy specimen is placed in a separate, labeled container*
- *Traditionally, only a single biopsy was obtained from the most abnormal appearing area of the cervix*
- *Some of the reasons for limiting the number of biopsies were that biopsies are painful*
- *Detection of CIN is enhanced by obtaining multiple biopsies*



# ***Biopsies***

- ***Biopsies may be taken from any part of the most abnormal appearing area or from more than one abnormal appearing area***

## ***order of taking the biopsies***

- ***Should be from posterior to anterior; to avoid bleeding that blocks visualization of the other biopsy sites***
- ***Ferric subsulfate (Monsel's solution) is applied with either small or large cotton swabs to the biopsied areas to control bleeding***
- ***In case of significant bleeding, surgical and/or vaginal packs***

# ***order of taking the biopsies***

- ***For patients at an increased risk of bleeding, care should be taken to obtain very small biopsies and limit the number of biopsies obtained***
- ***Patients with risk factors for complications should be referred to an experienced clinician for colposcopy, if available***

# *Endocervical curettage*

- *In our practice, we perform ECC at colposcopy in all nonpregnant patients*
- *Approximately 5 to 15 percent of patients with high-grade CIN are diagnosed solely based on the ECC specimen*
- *Some data suggest that ECC increases the sensitivity of the examination, particularly in older women*
- *In addition, ECC may sample cells from "skip lesions" (noncontiguous lesions) that are typical of glandular neoplasia*
- *Some clinicians do not perform ECC in all patients*

***If selective use of ECC is performed,  
the indications are***

- ***ASC-H***
- ***HSIL***
- ***Atypical glandular cells***
- ***adenocarcinoma in situ***



## ***Indication of ECC in ASC-US or LSIL***

- ***No lesion is visualized during the colposcopic examination***
- ***Colposcopy is inadequate***
- ***Ablative treatment is contemplated***
- ***Transformation zone is not clearly visible***

# **ECC**

- *To perform an ECC, a long straight curette is inserted into the endocervical canal and used to scrape the four quadrants of the canal*
- *An endocervical brush is then inserted and rotated to remove any exfoliated tissue*
- *A drop of mucus and blood is often seen at the os after ECC, and this should be included*

# ***ECC contamination***

***In women in whom the transformation zone has receded into the cervical canal :***

- ***postmenopausal women***
- ***Women with a prior cone biopsy***
- ***Ablative therapy***

# ***Management positive ECC***

- *If the cervical cytology was HSIL and the ECC is positive, even if there is suspicion of contamination, treat with excisional biopsy*
- *If the cytology was LSIL, continued follow-up without excisional surgery is reasonable*
- *An ECC that does not show endocervical tissue is an inadequate result and cannot be construed as a negative result*
- *In such cases, if the result may impact management, repeat sampling should be performed*

# ***Adequate Examination***

- *The entire SCJ and transformation zone are visualized circumferentially around the external os*
- *The margins of any visible lesions must be fully identified*
- *The histologic results from biopsies of the lesions should explain the abnormal cytology (ie, if the cytology was high grade and all biopsies are normal, then the examination was not adequate)*

# ***Documentation should include***

- ***Visualization of the SCJ Whether the SCJ was fully or not fully visualized has been referred to previously as "adequate" or "inadequate" examination***
- ***In the new ASCCP guidelines, "adequacy" has been replaced by documentation of the SCJ was or was not fully visualized***
- ***Size and location of abnormalities***
- ***Whether the vagina or vulva were evaluated should be clearly noted***



# ***Follow-up***

- ***Avoid vaginal intercourse for 48 hours after cervical biopsy to minimize trauma and bleeding***
- ***The provider should review the cytology and histology results and his/her colposcopic findings with consideration of the patient's age, medical conditions, and prior cervical cytology, HPV results, and histology history before establishing a diagnosis and management plan***


# *Follow-up*

- *If cytology is either suggestive of possible malignancy or shows malignant cells, the colposcopic examination will not be adequate unless biopsy confirms the presence of cancer*
- *In this situation, if invasive disease is not found, and a lesser lesion such as CIN 3 is detected, repeat colposcopy by a more experienced colposcopist and review of the referring cytology slide is appropriate before considering more invasive intervention*

# Complications

- *Bleeding or infection at the biopsy site*
- *Significant bleeding and infection are rare*
- *For bleeding, apply ferric subsulfate (Monsel's solution) with either small or large cotton swabs to the biopsied areas*
- *If necessary, sustained pressure with a cotton swab or silver nitrate sticks may also be used*
- *In rare cases of significant bleeding, the vagina can be packed to apply pressure to the cervix*
- *Ferric subsulfate solution and silver nitrate interfere with interpretation of biopsy specimen, so these substances should not be applied until after all biopsies have been taken*

# *Effectiveness*

- *The efficacy of colposcopy*  *experience and training of the colposcopist*
- *Ability of the colposcopist to interpret the colposcopic findings and obtain properly directed biopsies*
- *Among experienced colposcopists, there is good interobserver agreement for normal epithelium, CIN 2, 3, and invasive cancer*
- *There is more interobserver variation in diagnosis of CIN1*
- *However, this lack of agreement is also true for histopathologic diagnosis of these entities*
- *Performing two or more biopsies appears to increase sensitivity*

باتشكر

